




ALLIANCE™

[.https://www.globalseafood.org](https://www.globalseafood.org)Health &
Welfare

Four AHPND strains identified on Latin American shrimp farms

3 February 2017

By Jee Eun Han, D.V.M. Ph.D. , Kathy F.J. Tang, Ph.D. , Luis F. Aranguren, Ph.D. , Patharapol Piamsomboon, D.V.M., Ph.D. and Seung Hye Han, M.A.

EMS update: First report on pathogenic *Vibrio campbellii* strains

Acute hepatopancreatic necrosis disease (AHPND), also commonly known as Early Mortality Syndrome (EMS), is a serious, major global disease of farmed shrimp that causes hepatopancreas dysfunction and secondary *Vibrio* infections and can result in 100 percent mortality in the animals' juvenile stages.

The disease started in China in 2010 and has currently spread to aquaculture facilities in Vietnam, Malaysia, Thailand, the Philippines, Mexico and much of Latin America. Losses from EMS have been estimated to exceed \$1 billion per year.

The literature reports AHPND as caused by a unique strain of *Vibrio parahaemolyticus*, an ubiquitous bacterium that colonizes uneaten feed and organic sludge in culture pond bottoms, and also the chitinous shrimp molts and the animals' stomach linings, and is transmitted horizontally from shrimp to shrimp and vertically from spawner to egg. Here we present the first report describing the pathogenicity of non-*V. parahaemolyticus* AHPND strains.



AHPND is a major global disease of farmed shrimp that seriously affects the industry in many countries in Asia and Latin America. Photo by Darryl Jory.

Bacterial isolation and AHPND identification

Four *Vibrio* strains (16-902/1, 16-903/1, 16-904/1 and 16-905/1) were isolated from either stomachs of diseased shrimp or sediment samples from AHPND-affected farms in Latin America during 2016. Bacterial identifications were carried out using 16S rRNA sequencing and *Vibrio*-specific PCR assays targeting *hly* gene. These bacteria were grown on TSB+ (Tryptic soy broth plus 2 percent NaCl) at 28-29 degrees-C with gentle shaking (100 rpm) and further tested for AHPND PCR assays with primers targeting *pirAB_{vp}*.



(<https://ashored.ca>).

By the PCR assays, these 4 strains were identified to *V. campbellii* by 16S rRNA sequence analysis and *hly* gene PCR. These *V. campbellii* strains had both *pirA_{vp}* and *pirB_{vp}* genes (Table).

AHPND pathogenicity bioassays

We determined pathogenicity of a representative AHPND *V. campbellii* strain (16-904/1) by shrimp bioassays. Three 90-L tanks were filled with artificial seawater (salinity of 25 ppt and temperature at 28 degrees-C), and specific-pathogen free (SPF) *P. vannamei* (N=20, weights: 2.0 g) were stocked in each tank. For the infection, each strain was cultured in TSB+ overnight with gentle shaking (100 rpm) to reach 1×10^9 CFU/mL, and shrimp were exposed the bacterial culture by immersion at a concentration of 2×10^5 CFU/mL water. Shrimp were monitored for mortality every 12 hr. Also, AHPND *V. parahaemolyticus* strains, 13-028/A3 (Vietnam strain, 2013) was tested as a positive control.

During the assays, no mortality was observed during the five-day bioassay period in a negative control. However, the *pirAB_{vp}*-containing *V. campbellii* strain 16-904/1 caused AHPND in *P. vannamei* and all the shrimp became moribund or died within two days, same as a positive control (Table).

Show entries

Strain	Origin (year)	VpPirAB (a)	Pathogenicity (b)
AHPND <i>V. campbellii</i> 16-902/1	Latin America (2016)	Pos	Not determined
AHPND <i>V. campbellii</i> 16-903/1	Latin America (2016)	Pos	Not determined
AHPND <i>V. campbellii</i> 16-904/1	Latin America (2016)	Pos	Pathogenic
AHPND <i>V. campbellii</i> 16-905/1	Latin America (2016)	Pos	Not determined
AHPND <i>V. parahaemolyticus</i> 13-028/A3	Vietnam (2013)	Pos	Pathogenic

Showing 1 to 5 of 5 entries

Previous Next

Histopathology

For histopathology, shrimp were fixed in Davidson's alcohol-formalin-acetic acid (AFA), and analyzed for histopathology. The Davidson's AFA-fixed samples were processed, embedded in paraffin, and sectioned (4 μ m thick) in accordance with standard methods. After staining with hematoxylin and eosin (H&E), the sections were analyzed by light microscopy.

Negative control (non-AHPND *V. parahaemolyticus*) showed the normal appearance of the hepatopancreas (Figure A). However, shrimp challenged by *pirAB_{vp}*-containing *V. campbellii* strain 16-904/1 were confirmed to AHPND by histological examination (Figure E&F). The histological signs

showed a severe necrosis of hepatopancreas tubules with a massive sloughing of epithelial cells, and hemocytic infiltrations in severely affected tubules in the shrimp. The mortality and the histological signs were even higher than that of positive controls (AHPND *V. parahaemolyticus*) (Figure G&H).

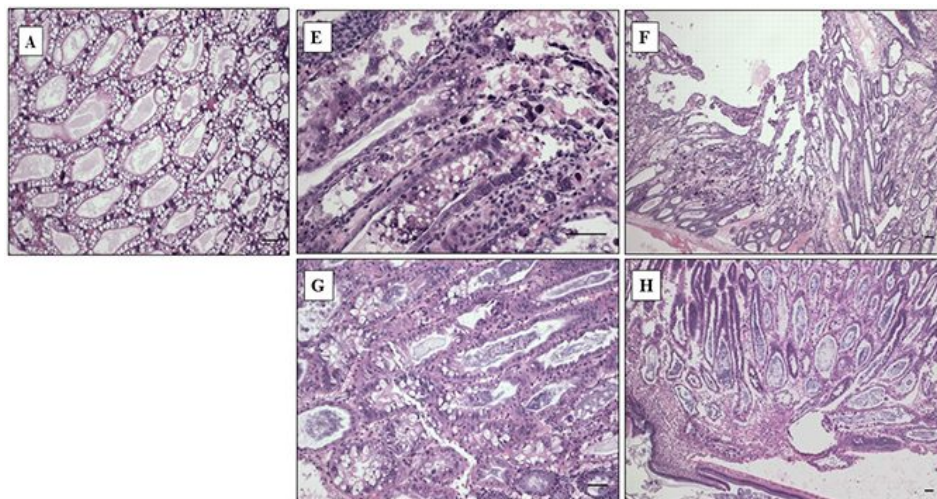



Figure A to H. Histopathological features of the hepatopancreas of shrimp *P. vannamei*. The shrimp were challenged by non-AHPND *V. parahaemolyticus*, AHPND *V. campbellii*, and AHPND *V. parahaemolyticus* strains. (A): Negative control (non-AHPND *V. parahaemolyticus*), showed the normal appearance of the hepatopancreas, (E & F): Shrimp challenged by AHPND *V. campbellii* strain showed the typical acute phase with progressive necrosis and massive sloughing of hepatopancreatic tubule epithelial cells, (G & H): Shrimp challenged by AHPND *V. parahaemolyticus* strain (positive control) showed a typical terminal phase characterized by massive bacterial infection sloughing of hepatopancreatic tubule epithelial cells and hemocytic infiltration. Mayer-Bennett hematoxylin/eosin-phloxine staining. Scale bars = 60 μ m.

Perspectives


Our findings of 4 *pirAB_{vp}*-containing *V. campbellii* strains confirm that these strains are pathogenic to shrimp in bioassays and cause AHPND. This is the first report describing the pathogenicity of non-*V. parahaemolyticus* AHPND strains. These findings confirmed that *pirAB_{vp}* are the virulence genes responsible for AHPND and also indicate a horizontal gene transfer between different bacterial species (from *V. parahaemolyticus* to *V. campbellii*) in natural ponds.

Authors

**JEE EUN HAN, D.V.M. PH.D.**

Corresponding author
CJ CheilJedang Feed & Livestock Research Institute,
CJ Blossom Park,
Suwon-si, Gyeonggi-do, Korea

hanje1223@gmail.com (<mailto:hanje1223@gmail.com>).

**KATHY F.J. TANG, PH.D.**

School of Animal and Comparative Biomedical Sciences
University of Arizona
Tucson, AZ 85721 USA

fengjyu@email.arizona.edu (<mailto:fengjyu@email.arizona.edu>).

**LUIS F. ARANGUREN, PH.D.**

School of Animal and Comparative Biomedical Sciences
University of Arizona
Tucson, AZ 85721 USA

lfarangu@email.arizona.edu (<mailto:lfarangu@email.arizona.edu>).

**PATHARAPOL PIAMSOMBOON, D.V.M., PH.D.**

School of Animal and Comparative Biomedical Sciences
University of Arizona,
Tucson, Arizona, USA

ake11122@hotmail.com (<mailto:ake11122@hotmail.com>).



SEUNG HYE HAN, M.A.

Department of Public Administration,
Yonsei University
Seoul, Korea

orchid02@yonsei.ac.kr (<mailto:orchid02@yonsei.ac.kr>).

Copyright © 2024 Global Seafood Alliance

All rights reserved.