




ALLIANCE™

(<https://www.globalseafood.org>).




 Health & Welfare

# EMS/AHPNS: Infectious disease caused by bacteria

1 July 2013

By Loc Tran , Rita M. Redman , Donald V. Lightner, Ph.D. and Kevin Fitzsimmons, Ph.D.

## Histopathology presents as an acute progressive degeneration of the hepatopancreas



Gross signs of AHPNS in shrimp include an empty stomach (left), a pale atrophied hepatopancreas and an empty midgut.

The shrimp-farming industry in Asia, the largest and most productive region in the world, was affected in 2009 by an emerging disease called early mortality syndrome or, more descriptively, acute hepatopancreatic necrosis syndrome. AHPNS began to cause significant production losses in southern China, and by 2012 had spread to farms in Vietnam, Malaysia and Thailand.

AHPNS has not only caused serious losses in terms of production and revenues in affected areas, but has also been responsible for secondary impacts on employment, social welfare and international market presence. The disease has caused significant shortages of shrimp products for the global market, which in turn impacted the global price of shrimp.

## Pathology

AHPNS usually occurs within 45 days in shrimp ponds with newly stocked postlarvae of both black tiger shrimp (*Penaeus monodon*) and Pacific white shrimp (*Litopenaeus vannamei*). The gross signs of AHPNS are evident in pond-side examinations of affected shrimp accompanied by dissection and examination of the hepatopancreas organs of the shrimp.

Shrimp with early AHPNS show pale to white coloration of the hepatopancreas, as well as atrophy that can reduce the size of the organ by 50 percent or more. In the terminal phase of the disease, black streaks or spots due to melanin deposition from hemocyte activity appear in the hepatopancreas. Mortality in affected shrimp ponds can approach 100 percent within a few days of disease occurrence.



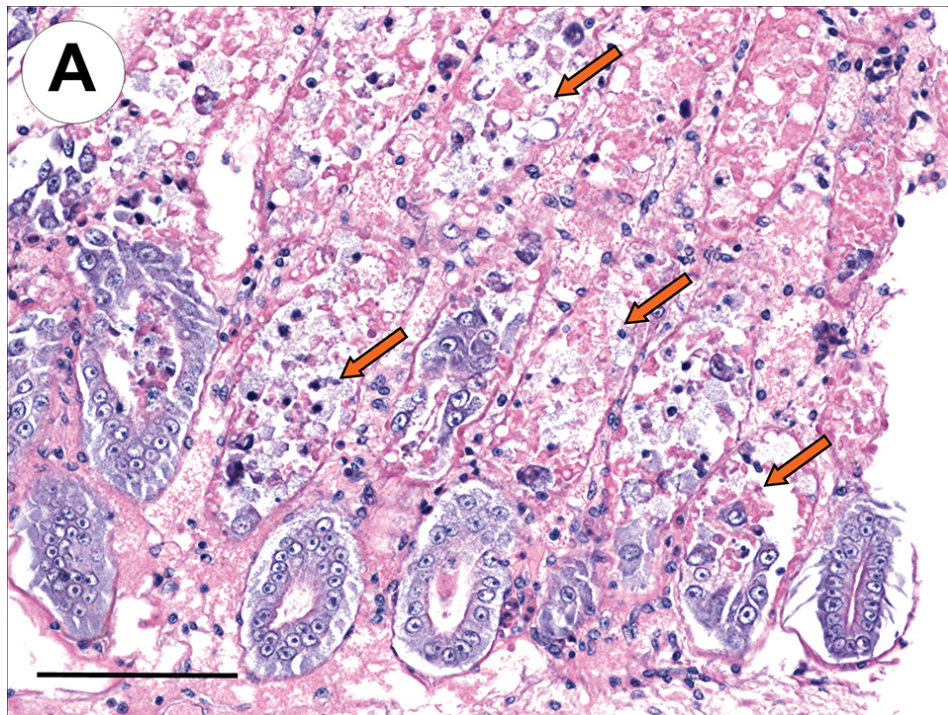
<https://link.chtbl.com/aquapod>

The histopathology of AHPNS presents as an acute progressive degeneration of the hepatopancreas from proximal to distal with dysfunction of tubular epithelial cells. Such cells round up and detach from the affected tubules, and become necrotic within the tubules or the gut lumen. In the terminal phase of AHPNS, the hepatopancreas shows marked hemocytic infiltration and development of massive secondary bacterial colonization that occurs in association with the necrotic and sloughed epithelial cells. This unique pathology suggested that the primary lesions in the hepatopancreas are mediated by a toxin.

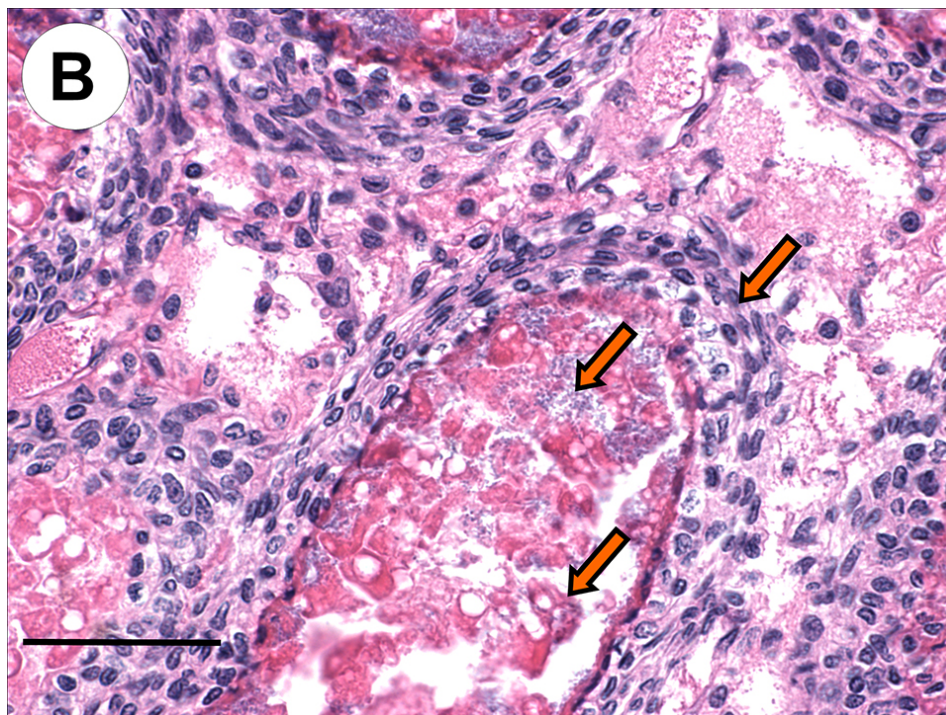
## Preliminary studies

Two approaches were initially undertaken by the University of Arizona Aquaculture Pathology Laboratory (UAZ-APL) to determine the etiology of AHPNS. The studies sought to identify a possible environmental toxin in water, sediments, and algae from affected ponds, feed samples and pesticides as the possible cause of the disease. Researchers also tested for potential infectious agents using frozen shrimp collected from affected farms in 2011 and 2012. None of the treatments were found to induce pathology consistent with AHPNS.

Because the initial studies did not pass the disease to the experimental animals, several site studies in an AHPNS-endemic area of Vietnam were conducted during middle and late 2012. The results from these studies showed that AHPNS lesions could be induced in experimental shrimp through feeding of infected non-frozen shrimp carcasses, cohabitation of infected and experimental shrimp, and immersion in a mixture of bacteria isolated from an infected shrimp's stomach. The mixed bacteria sample found to induce AHPNS was brought back to UAZ-APL for further characterization to determine the infectious nature and causative agent of AHPNS.



This histological section of a shrimp's hepatopancreas in a reverse gavage challenge test shows the lesions of an acute phase of AHPNS characterized by massive sloughing and necrosis of the tubular epithelial cells (arrows). Scale bar = 100  $\mu$ .



This histological section of a shrimp hepatopancreas in an immersion challenge test shows an advanced stage of AHPNS characterized by hemocytic inflammation, bacterial infection and massive sloughing and necrosis (arrows, top to bottom). Scale bar = 50  $\mu$ .

## Infectivity studies

Challenges by immersion or reverse gavage via an anal route to the hepatopancreas were employed using the mixed bacteria isolated from the AHPNS-infected shrimp in Vietnam. Experiment 1 was an immersion study with the mixed bacteria, while experiment 2 used immersion with individual bacterial isolates from the mixed culture. Experiment 3 was an immersion bioassay with individual bacteria colonies isolated from AHPNS-positive treatments of experiment 2 and reverse gavage of filtered broth fluid inoculated with a pure culture of a pathogenic bacterial colony.

Immersion in the mixed bacteria-induced mass mortality and AHPNS pathology identical to that of affected field specimens. The most dominant bacterial colony isolated from the mixed culture was also able to cause mass mortality and AHPNS lesions in experimental shrimp in the immersion challenge of experiment 2. The same type of bacterial colony recovered from the animals challenged in experiment 2 could also cause the same pathology in shrimp in subsequent experiments, thus confirming that AHPNS is caused by an infectious agent.

Interestingly, the cell-free supernatant fluid of the broth media inoculated with the pathogenic pure culture could induce the same AHPNS pathology in shrimp by reverse gavage. This evidence reinforced the initial assumption that the primary lesions of AHPNS are mediated by a toxin or toxins. Using biochemical and molecular biology tests, the bacterial culture found to induce AHPNS was identified as a strain of *Vibrio parahaemolyticus*.

## Human health, biosecurity implications

Some rare strains of *V. parahaemolyticus* produce the toxins thermal-stable direct haemolysin and thermal-stable related haemolysin, which are responsible for foodborne gastroenteritis in humans who consume undercooked seafood. Fortunately, the unique AHPNS-causing *V. parahaemolyticus* strain does not generate these toxins. Thus, the health implications for shrimp products from AHPNS-affected countries should not be higher than for shrimp products from AHPNS-free countries.

Since AHPNS is an infectious disease, a major concern for the industry is the spread of the disease. Several experiments carried out by UAZ-APL indicated that infected live shrimp and fresh (never frozen) shrimp tissues can effectively transmit the disease to “clean” shrimp. This implies that untested live and fresh shrimp from affected areas may pose a risk until a fast and reliable test for detection of AHPNS is available. Because the AHPNS agent is localized in shrimp gastrointestinal tracts, headed and deveined fresh shrimp pose a lower risk than head-on and unveined fresh shrimp.

Concerning the viability and survivability of the agent of AHPNS in frozen shrimp products, several experiments conducted by UAZ-APL found that frozen infected shrimp collected from Vietnam did not cause AHPNS pathology in “clean” experimental shrimp, indicating the bacteria was not transmitted.

All evidence to date indicates the agent is inactivated by freezing and thawing. This implies that frozen shrimp products are unlikely to carry the transmissible agent of AHPNS. Hence, the risk of transmission of the disease from frozen commodity shrimp products to farmed and wild shrimp in importing countries appears to be minimal.

## Future research

Future studies will further elucidate the involvement of a phage in either toxin production or conferring increased pathogenicity to the bacteria. Toxin(s) and toxin-producing genes of AHPNS-causing bacterial strains will be analyzed as potential targets for enzyme-linked immunosorbent assay testing and polymerase chain reaction diagnostics. Several approaches are under investigation to develop viable solutions for the detection and control of AHPNS.

*(Editor's Note: This article was originally published in the July/August 2013 print edition of the Global Aquaculture Advocate.)*

## Authors

---



### LOC TRAN

Aquaculture Pathology Laboratory  
School of Animal and Comparative Biomedical Sciences  
University of Arizona  
Tucson, Arizona 85721 USA

[thuuloc@email.arizona.edu](mailto:thuuloc@email.arizona.edu) (mailto:thuuloc@email.arizona.edu)



**RITA M. REDMAN**

Aquaculture Pathology Laboratory  
School of Animal and Comparative Biomedical Sciences  
University of Arizona



**DONALD V. LIGHTNER, PH.D.**

Aquaculture Pathology Laboratory  
School of Animal and Comparative Biomedical Sciences  
University of Arizona



**KEVIN FITZSIMMONS, PH.D.**

Department of Soil, Water and Environmental Science  
University of Arizona  
Tucson, Arizona, USA

Copyright © 2024 Global Seafood Alliance

All rights reserved.